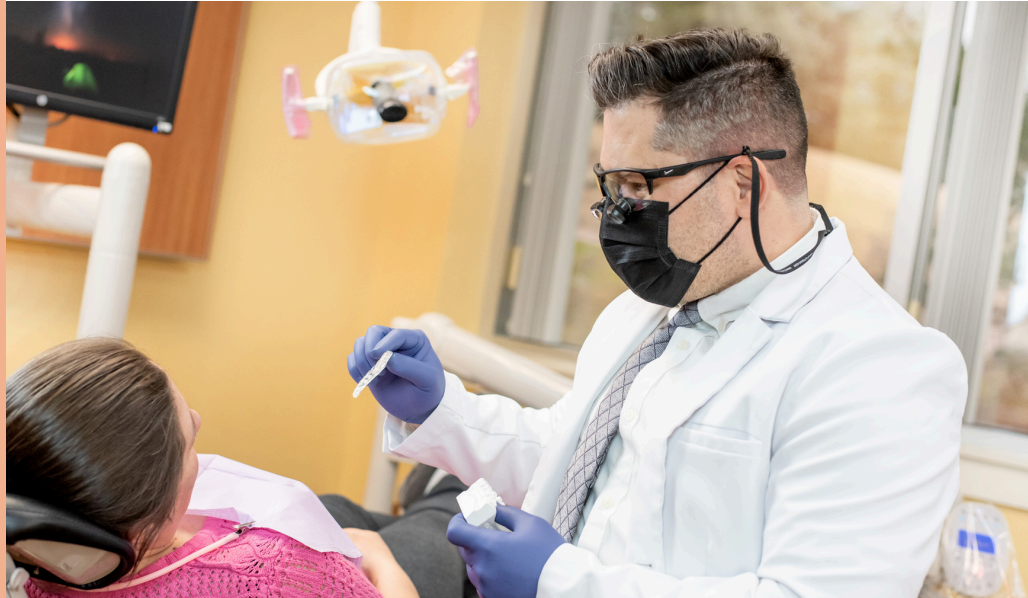

NEWSLETTER

In this Article

The Wax Rim is as Important as Ever!

Arg! Another Zirconia Crown Fell Off: A Guide to Recementing Crowns



At **Colchester Dental Group**, our mission is to deliver comprehensive, high-quality care for your patients. Our prosthodontic specialists bring advanced training and expertise, making them invaluable partners in achieving exceptional outcomes. With a focus on the restoration and replacement of teeth, they are uniquely equipped to manage complex dental cases—from dental implants to full-mouth reconstructions—with precision and care.

By referring to us, you gain access to a collaborative, team-based approach to patient care. We can assist with treatment planning and are ready to step in on complex cases when needed, ensuring that your patients receive the best possible care. Together, we can grow as partners in delivering optimal results for your patients.

This seamless integration ensures a smooth treatment experience for both your patients and your dental team.



Meet Our Team

Meet Our Specialist



Bashar Ghoujal, DMD
Prosthodontist

THE WAX RIM IMPORTANT AS EVER

The concept of the wax rim provides an elegant starting point in identifying incisal edge length, midline position, and horizontal plane.

When collecting findings for a patient with obvious signs of what would be considered a worn dentition, the process of FGTP includes visualizing a wax rim. Once the teeth have worn, they then move to compensate, placing the teeth under consideration for restoration in the wrong place. A couple of questions arise while figuring out what is possible.

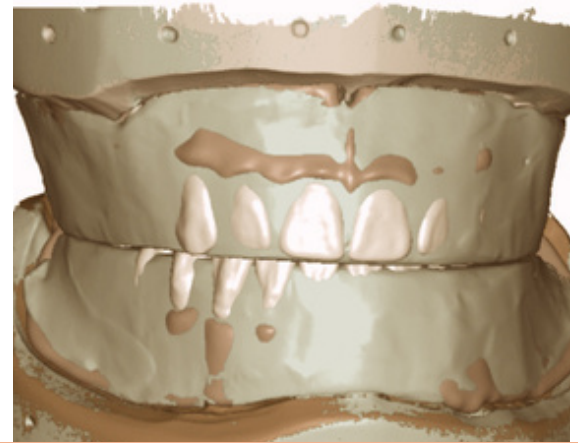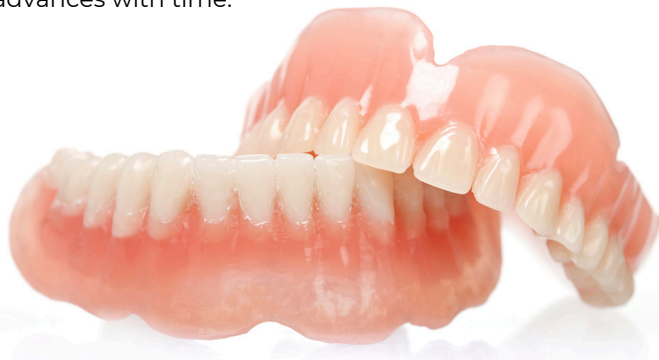- *Would orthodontic tooth movement improve the outcome for the patient?*
- *Moving ahead with a purely restorative solution decreases time in treatment, but at what cost, or what additional treatment may be required?*

"Prevent, Control, Resolve approach"

Moving into the "Prevent, Control, Resolve" approach championed by Dr. Jeff Rouse in thinking about airway, the focus at some point in the process becomes the maxillary arch width. The goal is to be aware of how the planned restorative treatment could impact the airway. We don't want to make it worse, which is where the concept of the wax rim and the connection to FGTP makes another appearance.

Returning to the edentulous patient, the lip support provided by the wax rim has been identified as the starting point before setting maxillary teeth. The L - T - R or Lip, Tooth, Ridge concept presented by Dr. Ricardo Mitrani and Dr. Darin Dichter begins with lip support, where the goal is to identify facial features for use as a reference point. This approach challenges the concept of simply setting the teeth over the edentulous ridge.

As old-school and analog as it appears, the wax rim and especially the concept of the wax rim remain as essential as ever. I'm looking forward to discovering how incorporation of the data provided by the wax rim advances with time.



The Wax Rim: A Fundamental Starting Point

Exploring the Limitations of a Completely Digital Workflow

One of the challenges in a digital-only protocol for making restorations for our edentulous patients arises at the point in the process traditionally reserved for wax rims. The clinical time spent at this stage aims to facilitate communication to the dental laboratory regarding the desired tooth position. Traditionally, the denture teeth would be positioned on a record base with wax, providing an opportunity for refinement at the next clinical visit. A digital workflow has the potential to rely more heavily on a wax rim created with intention. The concept is that the next appointment involves either a printed or milled version for use as either a trial prosthesis or potentially as the definitive prosthesis.

The wax rim informs the position of the teeth, while verification in the virtual design process emphasizes the detail transferred in terms of incisal edge position, occlusal plane, midline, and vertical dimension of occlusion.

A retentive record base supporting a refined wax occlusal rim is filled with information gained while working with the patient clinically. Once the information is scanned and digitized, it represents an important connection between analog and digital techniques, as the wax rim represents verified data in three dimensions. Whether the edentulous arches are scanned directly (intra-orally) or scanned indirectly (on stone models), selected reference points align the digitized version of the edentulous arch with the digitized version of the wax rim.

By Douglas G. Benting, D.D.S., M.S., F.A.C.P. is a member of Spear Resident Faculty.

References:

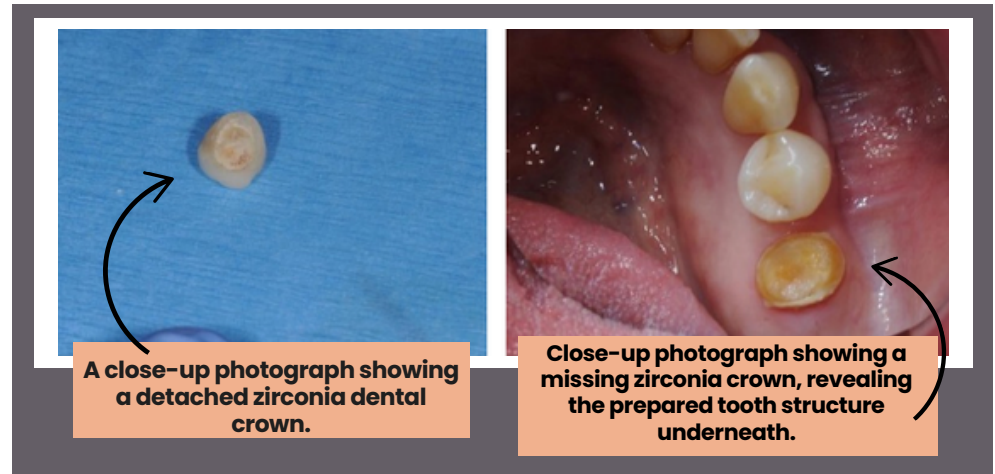
- Fang, Y., Fang, J. H., Jeong, S. M., & Choi, B. H. (2019). A technique for digital impression and bite registration for a single edentulous arch. *Journal of Prosthodontics*, 28(2), e519-e523
- Yan, Y., Yue, X., Lin, X., & Geng, W. (2023). A completely digital workflow aided by cone beam computed tomography scanning to maintain jaw relationships for implant-supported fixed complete dentures: A clinical study *The Journal of Prosthetic Dentistry*, 129(1), 116-124.
- Ahmed, W. M., Alhazmi, A., Alharbi, M. T., et al. (2023). Maxillary and mandibular complete-arch implant rehabilitation using a complete digital workflow: A case report *Journal of Prosthodontics*, 32(8), 662-668.
- Papaspyridakos, P., DeSouza, A., Bathija, A., Kang, K., & Chochlidakis, K. (2021). Complete digital workflow for mandibular full-arch implant rehabilitation in 3 appointments *Journal of Prosthodontics*, 30(6), 548-552.

ARG! ANOTHER ZIRCONIA CROWN FELL OFF: A GUIDE TO RECEMENTING CROWNS

“this is a common and disturbing occurrence for many dentists!”

"Arg!! Another zirconia crown fell off! I am so frustrated! It was recently cemented (December) with a universal self-adhesive cement (Rely-X Universal; 3M). Why does this keep happening? And what can I do to prevent it from happening again?" This aggravating and annoying situation comes from Ashley, one of our recent Restorative Design Workshop participants. Unfortunately, this is a common and disturbing occurrence for many dentists! Dr. Bob Winter and I hear this vexing scenario often. Zirconia crowns are one of the most used restorations by dentists.

Frustration echoed through the office as, yet another zirconia crown fell off prematurely. This situation is a common occurrence for many dentists. Zirconia, valued for its strength and durability, can present challenges in achieving reliable adhesive retention. This article explores essential steps and protocols for effectively recementing crowns, offering practical solutions to prevent such issues in dental practices.



A close-up photograph showing a detached zirconia dental crown.

Close-up photograph showing a missing zirconia crown, revealing the prepared tooth structure underneath.

➤➤ Zirconia Restoration Insertion: Key Protocols for Success ◀◀

When a previously cemented restoration comes off prematurely, it is crucial to observe where the old cement remains attached. This observation can provide clues to the origin of the breakdown. If cement is found within the intaglio of the restoration, it suggests that the tooth surface may not have been adequately prepared prior to cementation. Conversely, if the cement remains on the tooth itself, it indicates potential issues with the restoration preparation.

Regardless of the situation, both the restoration and the tooth must be thoroughly cleansed and managed to establish a durable connection. The following steps outline how to ensure accuracy when recementing crowns:

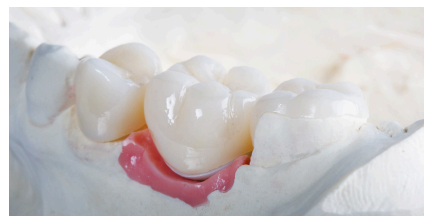1) Try-in and Check Margins

The marginal fit and contacts of the restorations are evaluated on the prepared tooth. Any contact adjustments are performed, and the surface is polished. Occlusal adjustment should be minimal until the restoration is adhered to the tooth. Adjustments are ideally performed with a fine diamond at low speed (less than 20,000 RPM) and then polished to a high shine. Using a handpiece at high speed creates flaws in the ceramic, which can lead to early fracture. Even if the zirconia is 3Y (and, to a lesser degree, 4Y) and can undergo transformational toughening, thereby limiting crack propagation, multiple high-speed applications create a limit to minimizing internal flaws. Crack defects and fractures can occur because of continued ceramic adjustments.

2) Air Abrade Tooth with 25-50 Micron Alumina Oxide

The tooth structure must be cleansed, free of biofilm and provisional cement debris prior to the adhesive process. These products will interfere with the adhesion of restorations to tooth structure and result in potential early and undesirable dislodgement. The very best way to debride the tooth surface is micro air abrasion with 25-50 micron alumina oxide particles. The second-best alternative is a slurry of pumice and a rubber cup.

(continued on next page)



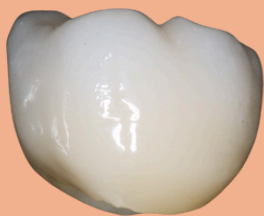3) Properly Isolate Tooth

Once the tooth is cleansed, it must be properly isolated to avoid contamination with saliva and crevicular fluids. Rubber dam, "Iso-lite," etc. are good retraction, evacuation devices. Cotton rolls can also be effective. Many times, retraction cords and hemostatic agents are necessary to remove gingival tissue interference and control any hemorrhage that may have occurred during tooth cleansing/air abrasion.

4) Clean Intaglio of Restorations

The inner surface of the restoration must be thoroughly cleansed. Organic contaminants will interfere with the adhesive ability and interaction of the zirconia. Zirconia has a high affinity for blood, lipids, saliva, and proteins from the try-in phase. The best method for cleansing the restoration is micro air-abrasion with 25-50 micron alumina oxide particles. This process provides a clean surface and incorporates a micro-mechanical roughness for cement interaction. Ivoclean provides an effective solution for cleaning the intaglio surface of zirconia crowns, offering a reliable alternative to the methods typically used.

It is best to air abrade the surface just prior to the adhesive process, as the surface is then "positively charged" and provides surface energy which ensures more intimate priming capability. The restoration does not need to be rinsed following air abrasion. Air flow will remove the excess alumina particles. Alternatively, there are a variety of chemical agents specifically designed to clean and prepare the intaglio aspects of ceramic restorations. Products like Ivoclean (Ivoclar), Katana Cleaner (Kuraray), and ZirClean (Bisco) all remove the organic contaminants of blood and saliva. Follow the manufacturers' directions to ensure proper surface preparation.



****Strength and Durability: Zirconia is incredibly strong and resistant to chipping and cracking, making it ideal for dental restorations that need to withstand chewing forces.***

5) Prime the Zirconia Surface

The surface of the zirconia must be activated or primed to create a chemical adhesion for the resin cement. Ceramic primers are designed for this purpose. The magic ingredient enabling this chemical connection to zirconia is 10-MDP monomer. Zirconia lacks glass particles, so etching the surface with hydrofluoric acid (common for glass ceramics like Lithium Disilicate) is unnecessary and ineffective. Monobond Plus (Ivoclar), a universal primer containing both 10-MDP and silane, is widely used for priming both zirconia and glass ceramics. If the crown was cleansed with a specific chemical cleanser such as Katana Cleaner or ZirClean, which contain 10-MDP, the surfaces are now primed and ready for the adhesive process. When applying primers, multiple applications are recommended, agitating each for 2 minutes. Solvent should be allowed to evaporate, followed by air-thinning to ensure complete solvent dissipation. It's important to note that Monobond Etch and Prime (Ivoclar) is not intended as an adhesive activator for zirconia, as it contains silane rather than 10-MDP, and is designed for priming glass ceramics.

6) Adhesive Resin Application

An adhesive resin is now applied to the primed intaglio surface. The purpose of the resin is to provide a "wetted" surface to facilitate better cement distribution. If the adhesive resin is a Universal Adhesive, it likely contains 10-MDP. Priming the zirconia restoration should still be conducted as a separate step. Universal adhesives contain various chemical ingredients and a significant amount of water to initiate chemical reactions for adhesion to enamel and dentin. It is well-documented that additional primers such as 10-MDP and silane may be deactivated by the complex chemistries and interactions occurring with Universal resins. Scotchbond Universal (3M) exemplifies one of many adhesive resins. The resin is applied in a thin layer to the intaglio of the crown. I do not light cure this applied layer. A thin layer of adhesive resin should also be applied to the prepared tooth structure. This step allows for dentin sealing. The literature recommends air-thinning this adhesive layer followed by complete light activation (cure). Polling dentists at the ARD Workshop, it is common practice not to cure this resin layer prior to the cementation process. The consensus and reason for this approach are concerns about improper or incomplete seating of the restoration due to resin thickness. A more viscous adhesive resin may exacerbate these concerns. The uncured adhesive resin will harden under the restoration upon light activation due to free radical activity. Again, Scotchbond Universal (3M) is among the many resin adhesives that may be used. If left uncured, it too will aid in the distribution of cement upon restoration insertion. (continued on next page)

7) Cementation

Cementing (versus bonding) is the most widely used process of adhesion for zirconia restorations. Adequate resistance and retention form of the tooth preparation allow for predictable cementation and restoration longevity.

Most clinicians prefer to cement zirconia rather than adhesively bond it. But if the protocols outlined above are followed precisely, the adhesive connection to zirconia is predictable.

Most dentists use RMGI or a self-adhesive cement as the luting agent for zirconia. Both are acceptable choices. If RMGI is used, the cement is allowed to cure (approximately 2 minutes; always follow manufacturers' instructions). The excess is then removed.

Alternatively, if a self-adhesive luting agent is used, the material is dual cured. For instance, if Rely-X Universal Self-adhesive (one of many alternative products) is used, the cement is applied to the intaglio of the restoration and distributed evenly in a thin layer. The restoration is seated on the tooth preparation.

Prior to removing the excess, a spot cure approach is used to initially harden the excess around the restorative margins (3-5 seconds). The excess is then nudged with the end of an explorer to break away or separate it from the marginal area. **The entire excess is not removed at this time!**

Once nudged, the cement is fully cured by light activation and allowed to self-cure (follow manufacturers' instructions). The hardened excess cement is then removed completely.

8) Occlusal Adjustment

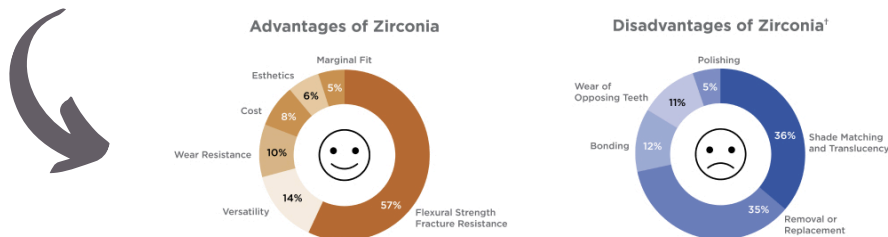
The now-luted restoration can be adjusted for any occlusal interferences that may be present. A fine diamond with low speed (20,000 RPM) is the recommended instrument and method of adjustment. This speed and grit will allow for minimal scratching and minimize the initiation of micro-flaws within the ceramic. Depending on the type of zirconia, micro cracks are possible. For instance, in 3Y zirconia, crack propagation is limited due to transformational toughening ("crack limiting").

Alternatively, with 4Y zirconia, the literature supports that initial occlusal adjustment may initiate the zirconia "crack limiting" process (depending on the alumina % within the zirconia itself), but continued or extensive adjustment can cause internal ceramic flaws and cracks. Care must be taken to avoid extensive adjusting procedures on any ceramic. Ceramic polishing measures must follow any ceramic occlusal adjustment. Well-polished zirconia is the most favorable ceramic surface for opposing natural tooth surfaces.

I hope this explanation of the zirconia cementation sequence is helpful to those of you who may be having problems or concerns about recementing crowns. Thanks to Ashley C. for her questions and concerns, which contributed to this Digest Article.

Jeffrey Bonk, D.D.S., is a member of Spear Resident Faculty.

The following diagram provides insight into why many dentists choose zirconia as the restoration material of choice.
*Charts on zirconia usage among 277 ACE Panel member dentists.



We truly appreciate you taking the time to read our newsletter. We value the opportunity to connect with our community and share insights about dental health and care.

- Colchester Dental Group

References

- Mehari, K., Parke, A. S., Gallardo, F. F., & Vandewalle, K. S. (2020). Assessing the effects of air abrasion with aluminum oxide or glass beads to zirconia on the bond strength of cement. *Journal of Contemporary Dental Practice*, 21 (7), 713-717.
- Sulaiman, T. A., Suliman, A. A., Abdulmajeed, A. A., & Zhang, Y. (2024). Zirconia restoration types, properties, tooth preparation design, and bonding: A narrative review. *Journal of Esthetic and Restorative Dentistry*, 36 (1), 78-84.
- McLaren, E. A., Maharishi, A., & White, S. N. (2023). Influence of yttria content and surface treatment on the strength of translucent zirconia materials. *The Journal of Prosthetic Dentistry*, 129 (4), 638-643.
- Lawson, N. C., & Maharishi, A. (2020). Strength and translucency of zirconia after high-speed sintering. *Journal of Esthetic and Restorative Dentistry*, 32 (2), 219-225.